

CASE REPORT

AN UNUSUAL CASE OF SWYER-JAMES-MACLEODS SYNDROME WITH DEXTROCARDIA

Sahana Sundarraju¹, Chandrashekar C², Gopal K³, Baby Sana⁴

HOW TO CITE THIS ARTICLE:

Sahana Sundarraju, Chandrashekar C, Gopal K, Baby Sana. "An Unusual Case of Swyer-James-Macleods Syndrome with Dextrocardia". Journal of Evolution of Medical and Dental Sciences 2015; Vol. 4, Issue 43, May 28; Page: 7556-7558, DOI: 10.14260/jemds/2015/1096

ABSTRACT: Swyer-James/MacLeod Syndrome (SJMS) is an uncommon disease with the characteristic radiological feature of "unilateral hyperlucency" due to loss of pulmonary vasculature and air trapping. SJMS is considered to be a form of bronchiolitis obliterans that follows viral bronchiolitis and pneumonitis. This report describes a rare case of Swyer-James syndrome with dextrocardia diagnosed in a 3 years old child during evaluation for recurrent respiratory infections.

KEYWORDS: Swyer-James/MacLeod syndrome; Unilateral Hyperlucency; Bronchiolitis obliterans; Chest X-ray; Dextrocardia.

INTRODUCTION: This syndrome was first described by Swyer and James in 1953 in a 6 years old boy who presented with recurrent respiratory infections. The chest radiograph of this patient showed relative hyperlucency of the right lung with significant reduction in vascular markings.¹ Bronchiolitis obliterans leads to reflex vasoconstriction and hypoperfusion causing hypoplasia of pulmonary vasculature leading to the development of hyperlucent pathologic lung.² We described in this article a paediatric patient presenting with this uncommon syndrome and dextrocardia.

CASE: A 3 years old girl was admitted for 7 days history of fever and cough (Figure 1). There was also, associated hurried breathing with chest indrawing throughout the day even when the child was afebrile. She was hospitalised at five months of age for similar episode of illness and had two more episodes last year for which she was treated on OPD basis. She did not have any chronic symptoms after these attacks.

On examination of respiratory system, she had 44 breaths/minute, with intercostal and subcostal retractions and flattened right chest with reduced movements, trachea deviated to the right side and decreased breath sounds on the right side with bilateral coarse crackles and rhonchi were heard in the lower lung fields. On cardiac examination her apex was felt in the right 4th intercostal space medial to midclavicular line with normal character. S1, S2 heard were normal with no audible murmur. Other physical findings were essentially normal.

Blood tests revealed leucocytosis with anaemia. Mantoux's test and sputum for AFB and blood culture were negative. On chest radiograph, there was a shift of trachea and mediastinum to the right side with collapse-consolidation in the RUL. The cardiac shadow was seen on the right side (Figure 2). CECT thorax done, showed dextrocardia with D-loop configuration and situs solitus. Mild volume loss of right hemi thorax with mildly reduced size of the right main pulmonary artery and mild compensatory hyperinflation of the left lung was seen (Figure 3). The radiological appearances were suggestive of Swyer-James/MacLeod syndrome.

She responded to the medical treatment of I.V antibiotics and nebulisations and was subsequently discharged with advice for regular follow-up.

CASE REPORT

DISCUSSION: SJMS presents with variable clinical features.^{3,4} The usual presentation of this syndrome in paediatric population is recurrent respiratory infections. SJMS is generally believed to be a post-infectious complication of viral bronchiolitis or pneumonitis acquired during early childhood.⁵ Patients can be completely asymptomatic with hyperlucent lung field being an incidental finding on the chest radiograph taken for other indications. The prevalence of SJMS was reported to be 0.01% in 17,450 survey of chest radiograph.² This syndrome is characterized radiographically by hyperlucency of a lobe, or the entire lung in the absence of obstructing mass with decreased vascular markings. Due to unknown factors it usually involves the left lung.³ Treatment is largely supportive with early control of super-added infections along with influenza and pneumococcal vaccination.⁶ Here, in our case, with history of recurrent respiratory tract infections, currently presented as an episode of pneumonia, was also diagnosed incidentally based on chest radiograph and CT. This case was also unusually associated with dextrocardia and situs solitus.

REFERENCES:

1. Swyer PR, James GCW. A case of unilateral pulmonary emphysema. *Thorax* 1953; 8: 133-6.
2. Yiu MWC, Tsang KWT, Wong Y, Ooi GC. Focal area of hyperlucency on a chest radiograph. *Respiration* 2001; 68: 545-7.
3. Abba AA, Al-mobeireek AF. Clinical spectrum of Swyer-James-MacLeod syndrome in adults. *Saudi Med J* 2003; 24: 195-8.
4. Lucaya J, Gartner S, Garcia-Pena P. Spectrum of manifestations of Swyer-James-MacLeod syndrome. *J Comput Assist Tomogr* 1998; 22: 592-7.
5. Erkasar CF, Caglar CE, Koray D, Ilgin KN. Bilateral Swyer-James (MacLeod') syndrome. *Indian J Pediatr* 2002; 68: 433-5.
6. Tortajada M, Gracia M, Gracia E, Hernandez R. Diagnostic considerations in unilateral hyperlucency lung (Swyer-James-MacLeod syndrome). *Allergol Immunopathol (Madr)* 2004; 32: 265-70.

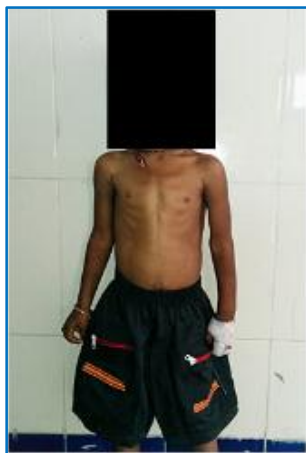

Fig. 1

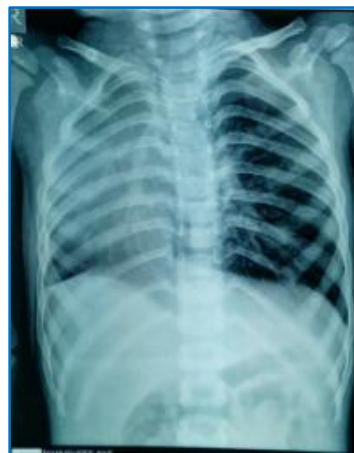

Fig. 2

CASE REPORT

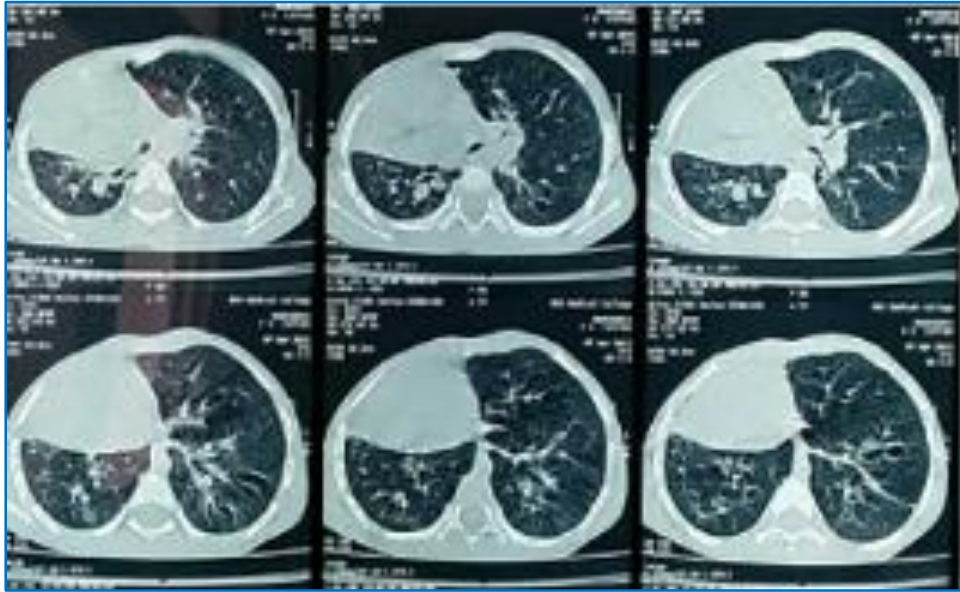


Fig. 3

AUTHORS:

1. Sahana Sundarraju
2. Chandrashekar C.
3. Gopal K.
4. Baby Sana

PARTICULARS OF CONTRIBUTORS:

1. Post Graduate, Department of Pediatrics, M.V.J Medical College & Research Hospital, Bangalore.
2. Assistant Professor, Department of Pediatrics, M.V.J Medical College & Research Hospital, Bangalore.
3. Professor, Department of Pediatrics, M.V.J Medical College & Research Hospital, Bangalore.

FINANCIAL OR OTHER

COMPETING INTERESTS: None

4. Post Graduate, Department of Pediatrics, M.V.J Medical College & Research Hospital, Bangalore.

NAME ADDRESS EMAIL ID OF THE CORRESPONDING AUTHOR:

Dr. Sahana Sundarraju,
#25,26, H.P.O & R.M.S Layout,
Shakthinagar, Kalyanagiri,
Mysore-570029.
E-mail: drsahana87@gmail.com

Date of Submission: 08/05/2015.
Date of Peer Review: 09/05/2015.
Date of Acceptance: 22/05/2015.
Date of Publishing: 28/05/2015.